

15-46 Chapter 15 Shoulder Arthroscopy

TABLE 15-3 Rehabilitation Protocol After Anatomic Coracoclavicular Reconstruction—cont'd

	ROM	Strengthening	Return to Sport/Work	Comments/Emphasis
12-20 weeks	Full ROM	Rowing exercises with tubing resistance progressing to isotonic scapular strength exercises (Blackburn exercises)	None	Strength exercises should target scapular muscles to promote stabilization and retraction of the scapula, thereby decreasing the load across the AC joint. When the patient can demonstrate active forward elevation without scapular asymmetry (symmetrical protraction of the medial border of the scapula during shoulder flexion and upward rotation and retraction during abduction), “Ts” and “Ys” are prescribed. Higher load exercises, including shoulder press, bench press, pullovers, and pectoral fly exercises, are performed until 24 weeks.
24 weeks	Full ROM	No restrictions	Full contact athletics or heavy labor allowed	While full contact athletics are allowed starting at 24 weeks, patients usually regain peak strength by 9-12 months.

AC, acromioclavicular; HEP, home exercise program; ROM, range of motion.

19

sc0030 **Arthroscopic Treatment of Shoulder Stiffness and Rotator Cuff Calcific Tendinitis**

Amit Nathani, Ryan A. Mlynarek, Asheesh Bedi

p1645 The stiff shoulder is a common and challenging problem for treating surgeons. The terms *adhesive capsulitis* and *frozen shoulder* are often used interchangeably in the literature, although these refer to distinct pathologies that cause shoulder stiffness. Numerous surgical and nonsurgical treatment options have been proposed, which reflect the lack of complete understanding of the disease process. The development of a responsible treatment plan requires accurate diagnosis of the various etiologies of shoulder stiffness due to dissimilar treatment approaches. The etiology includes primary adhesive capsulitis, secondary adhesive capsulitis, and iatrogenic (i.e., shoulder stiffness secondary to surgical intervention). Natural history and clinical outcome studies comparing surgical and nonsurgical management are rather limited, and there is a consensus on the need for robust studies to refine indications and improve clinical decision-making. This chapter describes the continued evolution of treatment as it relates to shoulder stiffness, focusing primarily on the technical aspects and outcomes of arthroscopic management.

PRIMARY ADHESIVE CAPSULITIS

s0500

Overview

s0505

The term *frozen shoulder* was initially coined by Codman p1650 in 1934 to describe a condition that is characterized by pain and reduced ROM at the shoulder.¹⁴⁶ Neviaser described the term as a “waste-can diagnosis” and stressed on the importance of differentiating between painful and stiff shoulder and a distinct pathologic entity termed *adhesive capsulitis*; his assertion was based on intraoperative findings of capsular fibrosis and inflammation.⁵⁰⁵⁻⁵⁰⁸ Nevertheless, the terms *frozen shoulder* and *adhesive capsulitis* continue to be used interchangeably. A recent survey of the American Shoulder and Elbow Society resulted in a consensus definition of frozen shoulder: “a condition characterized by functional restriction of both active and passive shoulder motion for which radiographs of the glenohumeral joint are essentially unremarkable except for the possible presence of osteopenia or calcific tendinitis.”⁷⁸¹ Adhesive capsulitis is classified

as primary or idiopathic, wherein an underlying etiology cannot be identified, or secondary, which has a similar histopathologic appearance but results from a known intrinsic or extrinsic cause.

p1655 The estimated incidence of adhesive capsulitis is between 2% and 5%, and the condition primarily affects women between the ages of 40 and 60 years.^{80,285,292,323,763} Other risk factors for adhesive capsulitis include diabetes,^{80,438,467,529} thyroid disease,⁷⁵⁹ and autoimmune disorders.^{94,606} The disease is poorly understood but thought to be a combination of synovial inflammation and capsular fibrosis that results from an imbalance in the local cytokine milieu. Increased expression of transforming growth factor β , platelet-derived growth factor, interleukin 1 β , tumor necrosis factor α , and vascular endothelial growth factor are found in the synovium.^{611,620} The result is a hyperplastic and neovascular tissue response leading to a capsule with highly fibroblastic properties, similar to that seen in Dupuytren disease.⁹⁵ The microscopic changes in tissue architecture parallel the four stages of adhesive capsulitis proposed by Neviaser and Neviaser, which are based on arthroscopic evaluation.²⁹³ Stage 1 and 2 are characterized by hypervascular synovitis, most prominently in the rotator interval, whereas stage 3 and 4 lack the acute inflammatory signs but show dense synovial thickening that typically involves the rotator interval, coracohumeral ligament, and anterior capsule extending into the inferior capsular recess.^{508,754} Clinical staging is more commonly used. Reeves described the stages of progression from painful freezing, through frozen, to thawing over a duration of 2 to 3 years.⁵⁹² The stages represent a continuum of disease, rather than discrete, well-defined phases.

p1660 The diagnosis of adhesive capsulitis is primarily one of exclusion, made from the history and physical exam. Though formal diagnostic criteria have not been developed, commonly referenced clinical findings include (1) a painful stiff shoulder for at least 4 weeks, (2) severe shoulder pain that interferes with activities of daily living or work, (3) nocturnal pain, (4) painful restriction of both active and passive shoulder ROM (forward elevation in scapular plane <100 degrees, >50% restriction of external rotation compared with contralateral side), and (5) normal radiographic appearance.⁸⁸ Plain radiographs should be obtained for all patients to rule out alternative sources of pain and stiffness, that may include osteoarthritis, calcific tendinitis, or rotator cuff disease. Though not routinely recommended, relevant MRI findings may include thickening of the coracohumeral ligament and rotator interval; the “subcoracoid triangle sign” or obliteration of the fat triangle, or subcoracoid fat between the coracohumeral ligament and the coracoid process, and a loss of the axillary recess indicative of contracture of the joint capsule and reduced joint volume (Fig. 15-44).^{128,217,462,694} The extent of shoulder range restriction tends to correlate with joint volume reduction.⁴¹⁹

s0510 Management

p1665 Adhesive capsulitis is a painful and debilitating disease, typically with a protracted course. In 1934, Codman

stated that “recovery is always sure and may be confidently expected” in patients with frozen shoulder, while advocating for nonoperative management. While many authors have characterized the natural history since then, management approach is still evolving and remains controversial. Some studies suggest that initial management with benign neglect, supervised neglect, home stretching programs, or formal physical therapy generally results in good outcomes,^{195,284} while others report long-term pain and a residual loss of motion.^{57,285,292,532} Miller et al. reported the disease process as completely self-limiting with all 50 patients followed for 10 years obtaining resolution of the disease, as measured by pain and ROM testing, with a home rehabilitation program and anti-inflammatory medication.⁴⁶⁷ Shaffer et al., on the other hand, reported residual pain and/or loss of motion in up to 50% of patients over a mean of 7 years of follow-up.⁶⁴⁶ The majority of the cited studies are case series that describe a single therapeutic approach, thus direct comparison is difficult. Studies commonly describe outcomes at time points greater than 1 year, which can be too long of a time period for patients to wait for relief of symptoms; thus clinical decision-making becomes further complex.

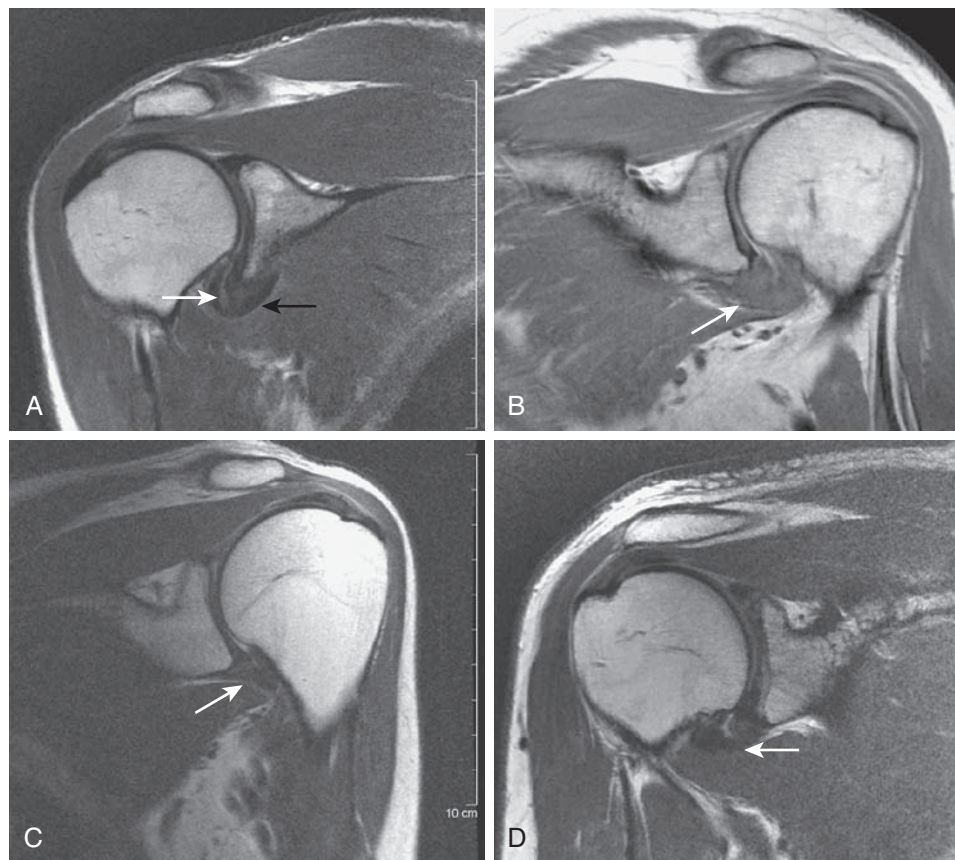
Nonoperative Management

s0515
p1670 Given the self-limiting natural history, the mainstay of initial treatment for adhesive capsulitis is nonsurgical. A number of nonoperative options exist and all have been shown to have positive short-term results. These include physiotherapy/home therapy,^{401,467,514} supervised neglect,¹⁹⁵ steroid injection,^{90,341} hydrodilatation,^{569,586,715} oral steroids,⁹¹ and nerve blockade.^{170,353} In our practice, we prefer formal physical therapy in combination with a home program. Intra-articular steroid injections are offered in cases where pain is a limiting factor. This corresponds to stages 1 and 2, where an inflammatory component is present. In a randomized study that looked at 93 patients, the combination of steroid injection and physical therapy was more effective treatment than injection alone, physical therapy alone, or placebo.¹²⁵ We do not routinely use the other aforementioned techniques. In refractory cases in which patients continue to have a passive mechanical block to motion after 6 months of therapy, we consider manipulation under anesthesia (MUA) and arthroscopic release.

Closed Manipulation

s0520
p1675 We do not routinely perform closed manipulation in isolation; however, in cases of refractory pain and stiffness in patients with primary adhesive capsulitis, it can be considered. Our preferred technique is manipulation followed by arthroscopy. Under general anesthesia or interscalene block, the patient is placed in the beach chair position. First, a gentle examination of passive shoulder motion is compared with that of the contralateral side. With the scapula stabilized with one hand, the other is used to grasp the distal humerus and manipulate

15-48 Chapter 15 Shoulder Arthroscopy



f0225

FIGURE 15-44: Magnetic resonance images demonstrating adhesive capsulitis. **A**, Stage 1 adhesive capsulitis. The inferior capsule (*black arrow*) is thickened. The synovium (*white arrow*) can be distinguished from the capsule and the inferior recess is maintained. **B**, Stage 2 adhesive capsulitis. The inferior capsule (*arrow*) is hyperintense and now markedly thickened. **C**, Stage 3 adhesive capsulitis. The inferior capsule (*arrow*) is hypointense, representing mature capsular scar. There is complete loss of the axillary pouch. **D**, Stage 4 adhesive capsulitis, with partial reconstitution of the axillary pouch and reappearance of synovium. The inferior capsule (*arrow*) is less thickened compared with stage 3. (Courtesy Hospital for Special Surgery, New York, NY.)

the extremity with a short moment arm to decrease chance of a torsional humeral fracture. First, forward flexion in the scapular plane is performed followed by external rotation with arm at the side. Often, audible and palpable yielding of tissue with minimal force confirms an effective manipulation. Passive terminal ROM is repeated and recorded. Outcomes of closed manipulation have largely been reported to be excellent^{201,225}; however, comparative studies have shown equivocal benefit when compared with home exercise therapy.³⁷¹ Farrell et al. showed patients who underwent closed manipulation for frozen shoulder achieved sustained improvements in ROM over a mean follow-up of 15 years.²²⁵ However, a more recent randomized controlled trial that compared patients undergoing MUA with a control group failed to show a benefit to manipulation; both groups showed similar improvement at all-time points up to 1 year.³⁷¹ A recent systematic review found an overall complication rate of 0.4% with MUA, with proximal humerus fracture being the most common.²⁷⁹ Others have reported complications such as glenohumeral dislocation, rotator cuff

and labral tears, and brachial plexus injuries. Typical findings during postmanipulation arthroscopy are hemiarthrosis and capsular tearing.⁴¹⁵ If ligament or tendon tearing is noted, this may suggest a need for improvement in the manipulation technique.

Arthroscopic Treatment

As stated earlier, our preferred technique for refractory stiffness is closed manipulation followed by arthroscopy. Arthroscopy has several advantages, including the opportunity to address any concomitant pathology such as debridement of synovitis, biceps-related pathology, and allows for a more controlled and complete capsular release not achieved with manipulation. The order of arthroscopy before or after manipulation is controversial. Performing the manipulation first may facilitate placement of the arthroscope into the joint and decrease the risk for chondral damage. Others advocate performing arthroscopy before manipulation, as any capsular tearing during manipulation will cause a hemiarthrosis and make

s0525

p1680

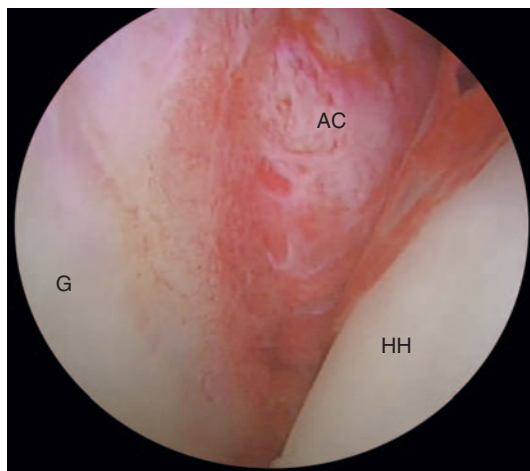
Chapter 15 Shoulder Arthroscopy 15-49

visualization more difficult. The plane of the traumatic capsular tearing created during manipulation may be unfavorable as well.

p1685 Arthroscopy is initiated using a standard posterior portal. A spinal needle-guided anterior portal is established under direct vision above the leading edge of the subscapularis and just lateral to the middle glenohumeral ligament. Depending on the stage of disease, there may be extensive synovitis in addition to capsular thickening (Fig. 15-45). A synovectomy can be atraumatically performed with a 4.5-mm motorized shaver. Next, the capsular release is performed with the aid of an arthroscopic radiofrequency device. The rotator interval is first released under direct visualization starting the capsular division anterior and inferior to the biceps tendon and continuing inferior to the upper edge of the subscapularis tendon (Fig. 15-46).²⁹⁸ In the prearthroscopic era, experience

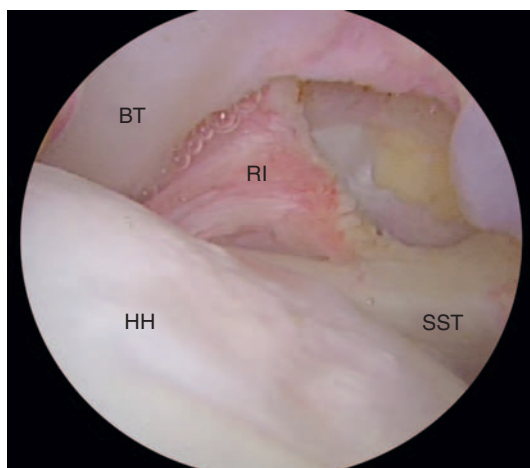
from open capsular release of the rotator interval has been reported to restore external rotation in patients with refractory adhesive capsulitis.⁵³⁶ With adequate release, the humeral head begins to become more mobile, moving inferiorly and laterally, thus allowing improved access to the anterior and inferior capsule. The release is now carefully continued anteriorly and inferiorly to include the middle glenohumeral ligament and anterior band of the IGHL all the way to the 6 o'clock position, and releasing the capsule in layers to protect the underlying subscapularis muscle belly and the adjacent labrum (Fig. 15-47). As one moves inferiorly, care is taken to perform this release in layers under direct visualization, to work from an "outside-in" technique, and to place the arm in adduction and external rotation to protect and minimize risk of injury to the axillary nerve. The arthroscope is removed and motion again tested. The arthroscope can then be switched to the anterior portal to examine the posterior capsule and to debride synovitis or release any capsular contracture to perform a complete 360-degree release if necessary, though our experience suggests that this is usually not required (Fig. 15-48). A recent systematic review found an overall complication rate of 0.6% during or following an arthroscopic capsular release, with superficial wound infection and brachial plexopathy cited as most common.²⁷⁹ We have had no cases of axillary nerve injury using the above technique.

Postoperatively, the goal is to maintain the intraopera- p1690
tive ROM that was achieved, provide adequate pain control, and begin immediate supervised therapy. An interscalene nerve block or indwelling catheter in the recovery room has been shown to be beneficial in allowing the patient to tolerate early motion following shoulder arthroscopy.^{84,370} Physical therapy with aggressive ROM and hydrotherapy is recommended 5 days per week for the first 2 weeks and three times per week until



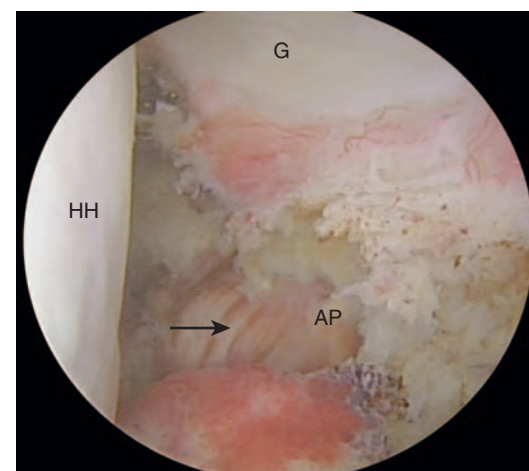
f0230

FIGURE 15-45: Arthroscopic view of a glenohumeral joint with stage 2 adhesive capsulitis prior to synovectomy or capsular release. The anterior capsule (AC) shows hypervascular synovitis and capsular proliferation. HH, humeral head; G, glenoid.



f0235

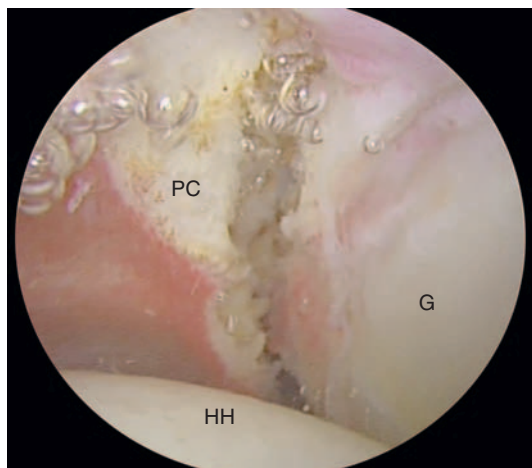
FIGURE 15-46: Arthroscopic view following rotator interval (RI) release between the long head of the biceps tendon (BT) and subscapularis tendon (SST). HH, humeral head.



f0240

FIGURE 15-47: Arthroscopic view following release of the inferior capsule in the axillary pouch (AP) using an outside-in technique. Underlying muscle fibers (arrow) can be visualized following adequate release. HH, humeral head; G, glenoid.

15-50 Chapter 15 Shoulder Arthroscopy



f0245

FIGURE 15-48: Arthroscopic view from the anterior portal show posterior capsule (PC) release. HH, humeral head; G, glenoid.

treatment is completed. A home program of stretching is also a critical component to optimize outcomes.

s0530 **Outcomes**

p1695 Arthroscopic capsular release has become more commonplace. The techniques have been well described and limit the scope for any intra-articular damage.^{573,734} A multitude of studies in the past few years have supported the role of arthroscopic release as safe and effective, particularly for the treatment of recalcitrant cases of frozen shoulder.^{43,52,142,212,665} In a level III comparison of MUA and arthroscopic division of the joint capsule, patients treated with arthroscopy were twice as likely to be pain free at 2 years' follow-up. Additionally, nine of the 20 patients treated with MUA alone had residual functional deficit compared with three of 20 patients treated with arthroscopy.⁵²⁸ Most recently, Le Lievre and Murrell reported that early gains in pain and motion after arthroscopic capsular release were maintained or enhanced over a mean follow-up duration of 7 years.³⁹⁶ There is some debate about how much of the capsule should be released. Jerosch described a 360-degree capsular release,^{345,535} as the posterior release is thought necessary to alleviate significant internal rotation deficit. However, a recent level III study that compared anterior release with anterior plus posterior release did not show any benefit to the more extensive technique.⁶⁶⁵ Another study showed early gains with combined anterior and posterior release, but longer-term outcomes were similar to those of isolated anterior release.¹³⁵

s0535 **Secondary Adhesive Capsulitis**

p1700 While primary adhesive capsulitis has been used to describe the idiopathic global capsular inflammation and fibrosis that occurs in the absence of other lesions, secondary adhesive capsulitis by definition is associated with intrinsic or extrinsic conditions that limit the shoulder

mobility. Intrinsic conditions that have been implicated include rotator cuff tears, bursitis, and tendinitis, while extrinsic factors may include trauma, repetitive overuse injuries, and surgical procedures, including arthroscopic thermal capsulorrhaphy, resection of calcific tendinitis, and capsular shift procedures.^{261,483} These conditions demonstrate isolated areas of capsular contracture that are histopathologically indistinguishable from idiopathic adhesive capsulitis, but occur concurrently with other known injuries or diseases.⁵⁰⁴ Distinguishing between idiopathic and secondary disease can be difficult and there is frequent overlap. Yoo et al. reported partial-thickness supraspinatus tears in 62% of patients with stage 2 idiopathic adhesive capsulitis diagnosed on MR arthrography.⁷⁷⁵ Clues from the history and physical examination can allow discrimination between primary and secondary disease. Patients with secondary adhesive capsulitis typically have a more acute onset of symptoms, present with day and night pain that typically occurs a few weeks after the insult. Physical therapy at this stage to prevent stiffness is often unsuccessful as any manipulation tends to exacerbate the symptoms. Treatment options include pain control and gentle stretching until the initial painful stage subsides. There is a paucity of literature regarding secondary adhesive capsulitis, but typically aggressive manipulation or surgery has not been recommended.^{508,733} Indeed, following the initial painful stage and after appropriate treatment of the patient's underlying etiology, the prognosis tends to be good. In some cases of recalcitrant frozen shoulder secondary to a post-traumatic or a postsurgical etiology, circumferential arthroscopic capsular release has shown good results, though the data are limited.⁵¹⁵ More research is needed to define surgical indications, if any, for this very heterogeneous group of disorders.

SECONDARY SHOULDER STIFFNESS

s0540

Overview

s0545

p1705 Shoulder stiffness following surgical intervention has numerous etiologies and should be distinguished from primary or secondary adhesive capsulitis. Shoulder stiffness is common following instability procedures, fracture surgery, and in the context of rotator cuff tears. Stiffness is typically preceded by a course of prolonged immobilization. While guided physical therapy is often the first-line treatment to regain motion, some authors advocate for a more aggressive approach given more unfavorable outcomes in the literature.⁷³³ Holloway et al. compared the results of arthroscopic capsular release in patients with primary frozen shoulder to those with postoperative and postfracture stiffness. Over a mean follow-up duration of 20 months, the postoperative stiffness group had significantly lower pain scores, patient satisfaction, and functional restoration compared with those in the other two groups.³¹² Gerber et al. reported similar findings on comparing the same three groups following arthroscopic

capsular release. At 26 months' follow-up, the Constant score, pain, ROM, and quality of sleep were least favorable in the posttraumatic group.²⁶²

s0550 Stiffness After Instability Procedures

p1710 Stiffness is one of the most common problems following shoulder arthroscopy, with overall rates estimated to be between 2.7% and 15%.⁷⁴⁵ Beyond postoperative morbidity, some patients are left with significant residual functional deficits.⁶⁴⁸ Stiffness following instability procedures can result from an excessively tightened anterior capsule, errant closure of an anatomic variant or sublabral foramen, and can lead to an internal rotation contracture. The humeral head is forced posterior, and this change in position can lead to failure of the posterior capsule and degeneration of the articular cartilage, a devastating result in the young patient (Fig. 15-49).⁴²⁰ Historical procedures that shortened the subscapularis tendon also led to this complication ("postcapsulorraphy" arthritis). Following a failed course of nonoperative treatment, arthroscopy has a role when stiffness is secondary to a capsular contracture. When external rotation is limited to less than 60% of the contralateral shoulder following these procedures, arthroscopic capsular release has shown good results.^{262,733,735}

s0555 Stiffness After Fracture

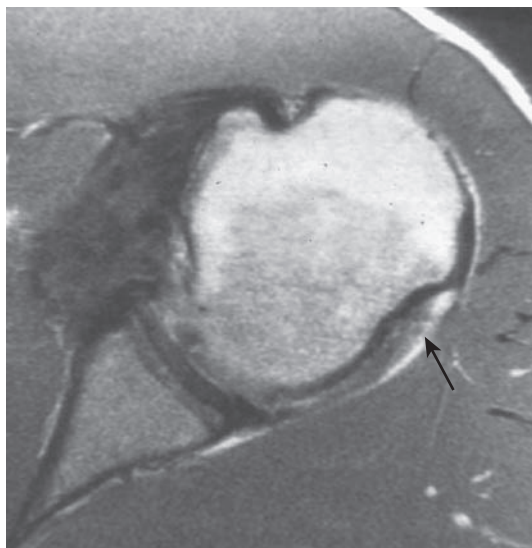
p1715 Fractures of the proximal humerus commonly lead to stiffness. Physical therapy is usually successful following fractures treated nonoperatively in the absence of malunion and secondary osseous impingement. Stiffness following open reduction and internal fixation can be due to a number of causes, which may include poor reduction and capsular, subdeltoid and subscapularis tendon

scarring. Though arthroscopy has a limited role, it can be considered prior to considering corrective osteotomy or arthroplasty. Burkhart described an arthroscopic subscapularis tenolysis for refractory stiffness following open fixation of a proximal humerus fracture. ROM was reestablished following arthroscopic capsular release of the middle glenohumeral ligament and of adhesions surrounding the subscapularis.⁹⁷ With proper patient selection, we have had good results in our practice with anterior-inferior arthroscopic capsular release and synovectomy in patients who have postfracture stiffness due to capsular contracture. More customary treatment is open surgical hardware removal with lysis of adhesions.

Stiffness and Rotator Cuff Disease

s0560
p1720 With respect to stiffness, rotator cuff surgery represents several challenges for the treating surgeon. An aggressive rehabilitation program in the early postoperative period places the repair at risk for failure, whereas prolonged immobilization may increase the likelihood of arthrofibrosis. Correctly identifying patients who are stiff preoperatively is equally as important as recognizing the postoperative patient who is developing stiffness. Stiffness and the presence of rotator cuff pathology is common.⁷⁷⁵ Regardless of etiology, the decision of whether or not to restore ROM before rotator-cuff repair is controversial. Tauro reported on 66 patients who underwent arthroscopic rotator cuff repair with a preoperative total ROM deficit less than 70% of the uninjured extremity. All patients had improved ROM postoperatively, and none required manipulation or further surgery. Of the 6 patients who underwent rotator cuff repair with a preoperative deficit greater than 70%, three required arthroscopic capsular release at an average of 5.5 months to regain ROM. He thus recommended repair after resolution of stiffness in such patients.⁶⁹⁵ Trenerry et al. reviewed 209 patients who had preoperative stiffness and who underwent rotator cuff repair and found that the only preoperative predictor of postoperative stiffness was hand behind the back motion.⁷¹³

Despite the best efforts of patients and surgeons, a small percentage of patients undergoing rotator cuff surgery become stiff and fail conservative management. In this group, closed manipulation or arthroscopic capsular release is supported to effectively restore motion and relieve pain.⁷³⁵ Care should be taken to ensure that the rotator cuff was not malreduced, and which may serve to limit postoperative passive and active ROM.



f0250

FIGURE 15-49: Axial magnetic resonance image demonstrating posterior capsular failure (arrow) following open capsular shift. (Courtesy Hospital for Special Surgery, New York, NY.)

CALCIFIC TENDINITIS

s0565

Overview

s0570

p1730 Calcific tendinitis is a relatively common disorder of unknown etiology characterized by a cyclical progression of reactive calcium hydroxyapatite crystal intratendinous

15-52 Chapter 15 Shoulder Arthroscopy

deposition, which is followed by spontaneous resorption and healing of the tendon. First described in the early 1900s, the condition may affect any tendon in the body; however, rotator cuff is most commonly involved.^{145,540,629} Reported prevalence of the disease varies between 2% and 20%, often identified as an incidental finding on chest radiographs.^{71,676} Welling et al. examined 925 patients presenting with a painful shoulder, and found an overall prevalence of 6.8%; the highest prevalence was amongst patients aged 31 to 60 years.^{676,748} Calcific tendinitis most commonly affects the “critical zone” of relative hypovascularity of the supraspinatus tendon (70% to 83%) as described by Moseley and Goldie^{322,416,491,571} (Fig. 15-50). Recent studies have indicated it is the result of a metaplastic cell-mediated transformation of tenocytes into chondrocytes, which then induce calcification.⁷¹⁷ These foci of metaplasia are then phagocytized

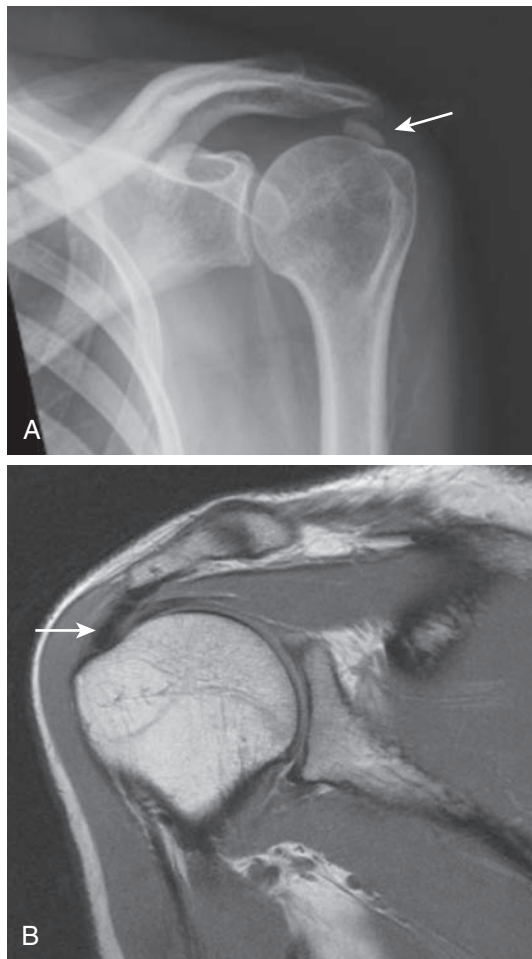
by giant cells and ultimately, the tendon remodels to reform normal tendon.¹⁷⁹ There are several classification and staging schemes to characterize the disease process, the details of which are beyond the scope of this chapter.^{189,224,252,276,417,483,553}

Nonoperative Treatment

Typically, calcific tendinitis is a self-limiting disease that causes low-grade pain and may be associated with concomitant shoulder stiffness. The condition tends to respond well to oral analgesics such as NSAIDs, physical therapy, and activity modifications. However, symptoms can be severe and long lasting and confer substantial disability.²⁵⁸ In patients who do not respond to conservative management, more invasive treatment options may be considered. There is no consensus on the preferred treatment, and therefore several options are available. The most common include SAI, ultrasound-guided needling and lavage (barbotage), and extracorporeal shock wave therapy. SAI is inexpensive, relatively low risk, and easy to perform. Many studies have shown an improvement in pain, ROM, and function after SAI when compared with placebo.^{1,4,61,566} In a randomized controlled trial by de Witte et al., patients in both SAI and ultrasound-guided barbotage treatment groups experienced improved pain and functional scores at 1-year follow-up. However, clinical outcome scores and radiographic calcification size was significantly better after barbotage.¹⁹³ Kim et al. recently published a randomized controlled trial that compared barbotage with extracorporeal shock wave therapy, finding improved clinical outcomes and decreased calcium deposit size in both groups, but the barbotage group experienced greater pain relief in the initial 6-month follow-up period.³⁶⁹ Although all above treatments are relatively safe with low complication rates, there is no evidence to assess their effectiveness when compared with a placebo control group given that this is a self-limiting disease.²⁵⁸

s0575

p1735



f0255

FIGURE 15-50: **A**, Anteroposterior radiograph of the left shoulder demonstrating a calcific deposit (*arrow*) located superior to the greater tuberosity. **B**, Magnetic resonance image of the right shoulder demonstrates an intratendinous calcific deposit (*arrow*) within the supraspinatus tendon. (Courtesy Hospital for Special Surgery, New York, NY.)

Arthroscopic Treatment

In our practice, patients presenting with signs and symptoms consistent with calcifying tendinitis of the rotator cuff are initially treated with NSAIDs and physical therapy. They are offered a SAI to improve pain, decrease inflammation, and facilitate better participation in physical therapy focusing on ROM exercises. They are counseled regarding the natural history of the disease process and the expected peak of inflammation and pain often experienced during the acute resorptive phase of the disease.⁷¹⁷ For those patients with severe, recalcitrant pain affecting ROM at the 6-month period, surgical treatment can be considered.

s0580

p1740

Surgical decompression was historically performed in an open fashion, but with advances in surgical technique and instrumentation over the past 20 years, arthroscopic decompression has become the gold standard treatment. Rubenthalar et al. performed a prospective randomized controlled trial of open versus

arthroscopic decompression in 38 patients and found equivalent clinical outcomes at 17-month follow-up.⁶¹⁸

p1750 We perform arthroscopic decompression in the beach chair position under general anesthesia combined with preoperative regional anesthesia for postoperative pain control. We obtain adequate orthogonal radiographs and 3D MRI prior to surgical incision to ensure adequate localization of the calcified deposits intraoperatively. Fluoroscopy is used if deposits are difficult to localize. The glenohumeral joint is first accessed using the posterolateral portal. A thorough diagnostic arthroscopic examination of the shoulder is performed and any concurrent pathology is addressed. Special attention is paid to the integrity of the rotator cuff insertion, and any partial- or full-thickness tears are noted for consideration of subsequent repair. If the calcium deposits can be visualized from the articular side, a passing suture is used to tag the location for evaluation from the bursal side. The subacromial space is then accessed via the same posterolateral portal. An anterolateral working portal is then established and an adequate bursal debridement is performed with a motorized shaver to maximize visualization and mobility within the subacromial space. The bursal surface of the rotator cuff is then evaluated for intratendinous calcium deposits. A probe is used from the anterolateral portal to evaluate the integrity of the rotator cuff and to palpate for intratendinous deposits. The location of the calcium deposits is compared with the preoperative radiographs, to ensure that all areas have been located intraoperatively. A needle can assist in localization of deposits, which often have the appearance of powdered sugar within the tendon. If necessary, fluoroscopy or ultrasound may be used. Sabeti et al. reported that the use of intraoperative ultrasound facilitates the detection of calcium deposits and significantly reduces the number of needle punctures to detect the deposits, thus decreasing operative time and increasing shoulder function outcome scores and pain relief at 2 weeks and 9 months of follow-up.⁶²¹ However, we appreciate the learning curve associated with using intraoperative ultrasound and therefore use fluoroscopy when localization is challenging. Once all deposits are localized, a percutaneous spinal needle is then used from the lateral approach in line with the rotator cuff fibers to approximate portal placement. A linear incision is made in the tendon, with careful attention paid not to violate the articular side of the tendon. A probe, switching stick or arthroscopic grasper is then used to mobilize the calcium deposits, while exercising due diligence to minimize iatrogenic damage to the tendon. Once the deposit is removed, a motorized shaver is used in oscillation mode with suction to remove any small fragments and floating debris. Confirmatory fluoroscopy may be performed to ensure adequate excision. Whether all calcium deposits must be excised is controversial in the literature. Porcellini et al. performed arthroscopic excision of calcium deposits in 63 patients and found that patients with residual calcifications detected on postoperative ultrasound at 2 years' follow-up achieved satisfactory functional outcomes, but a significant decrease in pain

relief when compared with those patients without residual calcifications.⁵⁷⁸ Other studies have failed to reproduce a significant difference in clinical functional outcomes or pain relief when residual calcifications are appreciated on postoperative imaging.^{18,428,644} It is our opinion that a balance must be achieved to excise as much of the calcium deposit as possible without compromising the integrity of the rotator cuff tendon that would then necessitate a large rotator cuff repair and rehabilitation course for the patient.

Once the calcium deposits have been removed, the p1755 integrity of the rotator cuff tendon is evaluated. Typically, the calcium deposits are localized from the bursal side alone and do not violate the articular side of the tendon. If there is only a small, partial-thickness defect of the bursal-sided tendon, we do not typically perform a repair. However, if the defect is full thickness or if the rotator cable is violated, then the rotator cuff is repaired. Often the defect is intratendinous and can be fixed with simple sutures across the linear tear. However, if the defect is U-shaped and has compromised a portion of the footprint, anchors are utilized and generally single-row fixation is sufficient.

After addressing the rotator cuff, attention is turned to p1760 the CA ligament and the acromion process. These are evaluated for fraying and signs of mechanical outlet impingement to assess the potential need for concomitant SAD. The need to perform a SAD is controversial in the literature.^{18,578,618,644,706} Authors generally agree that when subjective signs of mechanical impingement (fraying of the underside of acromion or CA ligament, presence of acromial osteophyte) are present, a SAD is warranted. However, Jacobs et al. performed arthroscopic excision of calcium deposits in 61 shoulders and concomitant SAD in those patients with fraying or degeneration of the CA ligament (14 of 61 shoulders) and found no significant difference in functional outcome scores between patients in whom a SAD was performed.³⁴² Balke et al. have recently published an attempt to objectively define radiographic parameters of the acromioclavicular relationship to better define the indication for SAD.³⁰ They found that the acromion index (AI) (described by Nyffeler et al.) in patients with calcifying tendinitis is similar to those patients presenting with subacromial impingement, but no difference in Bigliani classification, acromial tilt (AT) or lateral acromial angle (LAA) when patients with calcifying tendinitis were compared with a control group.^{56,522} Therefore we combine preoperative radiographic evaluation of the coracoacromial arch (AI, AT, LAA calculations) with the patient's history, physical examination for signs of impingement, and intraoperative findings to determine whether SAD is warranted on an individualized basis. If a SAD is planned, calcific deposit excision and possible rotator cuff repair is performed first to prioritize procedures prior to joint swelling and bleeding from acromioplasty.

Several studies have reported on the outcomes of p1765 arthroscopic calcium excision.^{18,31,216,347,483,578,591,644} Balke et al. published mid-term results of arthroscopic treatment of calcifying tendinitis in 70 shoulders with 6-year

15-54 Chapter 15 Shoulder Arthroscopy

follow-up. They report a significant improvement in functional outcome scores and improvement in pain.³¹ Although most commonly identified in the supraspinatus and infraspinatus tendons, calcific tendinitis has been successfully treated arthroscopically in various other locations.^{20,238,335} Vinanti et al. recently published excellent short-term results after arthroscopic calcium deposit excision from atypical locations about the shoulder (medial supraspinatus muscle belly, subscapularis tendon, and

the long head of biceps tendon).⁷²⁸ Complications following arthroscopic treatment of calcifying tendinitis are infrequently encountered, but may include infection, stiffness, neurovascular injury and rarely, ossifying tendinitis.^{463,520} Merolla et al. reported two cases of ossifying tendinitis following arthroscopic treatment of calcifying tendinitis, both of which were treated successfully with arthroscopic excision of the hydroxyapatite crystals in a histologic pattern of lamellar bone.⁴⁶³

sc0035 **Arthroscopic Management of Prearthritic and Arthritic Conditions of the Shoulder and the Postarthroplasty Shoulder**

Adam J. Seidl, Alexa Narzikul, Joseph A. Abboud

s0585 **INDICATIONS FOR ARTHROSCOPIC TREATMENT**

p1770 The utility of arthroscopy for treating glenohumeral arthritis has been recently questioned. The current American Academy of Orthopaedic Surgeons clinical practice guidelines classifies the use of arthroscopy for the treatment of glenohumeral arthritis as grade I, implying that they are unable to recommend for or against this option.³⁴⁰ Furthermore, a systematic review of the literature by Namdari et al. showed that arthroscopic debridement for glenohumeral arthritis lacks high-quality evidence to support its routine use.⁵⁰¹ Despite this, we have found that the utility and benefits of arthroscopic treatment of glenohumeral arthritis in certain clinical scenarios.

p1775 Any surgical treatment should be preceded by an adequate trial of conservative management that includes activity modification, physical therapy, antiinflammatory medication, and corticosteroid injections. Injectable viscosupplementation is an additional nonoperative treatment option, although there is a paucity of evidence that supports its use in the shoulder, and it is not currently approved by the Food and Drug Administration for injection in joints other than the knee.¹⁵³ When these nonoperative measures fail, TSA is considered the gold standard for treating severe glenohumeral arthritis. However, in some patients, a joint reconstruction is not desirable, possible, or practical, and arthroscopic treatment may be the best alternative. Elderly patients with significant medical comorbidities might be unable to tolerate the stresses involved with a major surgery; in these patients an arthroscopic intervention might be more suitable. Conversely, a young patient who has developed early onset arthritis might not be the best candidate for TSA due to concerns related to prosthesis longevity and/or the high functional demands of the patient.²⁸¹ Sperling

et al. studied the long-term outcomes of TSA and hemiarthroplasty in patients aged under 50 years and noted a 59% rate of glenoid lucency after TSA and a 68% rate of radiographic glenoid erosions after hemiarthroplasty. At a minimum follow-up of 5 years, more than 50% of patients in both the groups had radiographic findings that were of some concern.^{681,682} Finally, some patients (of any age) have significant pain, but diagnostic studies reveal only mild arthritic changes in the glenohumeral joint, making it difficult to justify the utility of arthroplasty in these patients.

Studies have shown that coexistent soft tissue pathology is common in patients with osteoarthritis.⁷⁴⁷ Arthroscopy provides an opportunity to diagnose and treat these secondary conditions, perhaps eliminating the need for arthroplasty. The benefits of a lower complication rate and quicker return to normal activities after arthroscopy compared with TSA make this scenario quite appealing.^{58,747}

Patients with shoulder pain do not frequently undergo arthroscopic surgery, and intraoperatively, significant arthritis is noted that was not observed on preoperative workup.²⁸⁸ Cameron et al. and Guyette et al. also found that preoperative radiographs and clinical examination were unreliable in predicting osteoarthritis that was intraoperatively documented.^{121,288} In these patients, it is crucial to know what can be arthroscopically performed to address unexpected osteoarthritis.

TECHNIQUE AND OUTCOMES

Standard Setup and Overview

At our institution, we typically perform shoulder arthroscopy in the beach chair position. A standard posterior